

terus Bicornis Bicollis, Imperforate Hemivagina and Ipsilateral Renal Agenesis Case Report and Literature Review

V DaCosta, L Christie, S Wynter, J Harriott, J Frederick

ABSTRACT

We present a case of a patient with Uterus bicornis bicollis, imperforate hemivagina and ipsilateral renal agenesis. This group of congenital malformations is often asymptomatic until puberty, when it presents as cyclic dysmenorrhoea, leucorrhoea or a pelvic mass. Magnetic resonance imaging is becoming the preferred modality for delineation of uterine malformations. When congenital abnormalities of the reproductive tract are encountered, a search should also be made for renal anomalies. Patients with Uterus bicornis bicollis and unilateral imperforate vagina are often seen with pain severe enough to mimic an acute abdomen. It is important to keep this unusual congenital malformation in mind in the differential diagnosis of vaginal discharge, pelvic mass and/or abdominopelvic pain in young women so as to avoid inappropriate surgical procedures.

Útero Bicorne Bicollis, Hemivagina Imperforada, y Agenesia Renal Ipsilateral Reporte de Caso y Revisión de la Literatura

V DaCosta, L Christie, S Wynter, J Harriott, J Frederick

RESUMEN

Presentamos el caso de una paciente con útero bicorne bicollis, hemivagina imperforada, y agenesia renal ipsilateral. Este grupo de malformaciones congénitas es a menudo asintomático hasta la pubertad, cuando se presenta en forma de dismenorrea cíclica, leucorrea, o una masa pélvica. La imagen por resonancia magnética se está convirtiendo en la modalidad preferida para delinear las malformaciones uterinas. Cuando se encuentran anomalías del aparato reproductor, debe realizarse también una investigación en busca de anomalías renales. A los pacientes con útero bicorne bicollis y vagina imperforada se les ve a menudo con dolores suficientemente severos como para parecer un abdomen agudo. Es importante tener en mente esta inusual malformación congénita en el diagnóstico diferencial del flujo vaginal, la masa pélvica y/o el dolor pélvico-abdominal en las mujeres jóvenes, a fin de evitar procedimientos quirúrgicos inadecuados.

West Indian Med J 2009; 58 (4): 379

INTRODUCTION

The true incidence of obstructive Müllerian anomalies is unknown but is believed to be between 0.1% and 3.8% overall (1). Double uterus is associated with a longitudinal vaginal septum and with a blind hemivagina in 10 – 30% (2, 3) of Müllerian anomalies. The incidence of imperforate hymen is estimated to be 0.1% (1) and transverse vaginal

septum 1 in 70 000 females, making these some of the rarest anomalies of the female genital tract (4). Awareness of these rare malformations should lead to early diagnosis and early surgical interventions resulting in reduced long-term morbidity (5, 6).

The longitudinal vaginal septum is produced by incomplete disappearance of the partition between the fused Müllerian ducts (7). The presentation of a complete obstructing hemivagina caused by a longitudinal vaginal septum may be associated with uterine malformation and ipsilateral renal agenesis (8–10). Obstructive anomalies prevent normal menstruation, allow for collection of blood in the uterus and the vagina and may increase the incidence of retrograde

From: Department of Obstetrics, Gynaecology and Child Health, The University of the West Indies, Kingston 7, Jamaica, West Indies.

Correspondence: Dr V DaCosta, Department of Obstetrics, Gynaecology and Child Health, The University of the West Indies, Kingston 7, Jamaica, West Indies. Fax: 927-0100; E-mail: ved111@hotmail.com

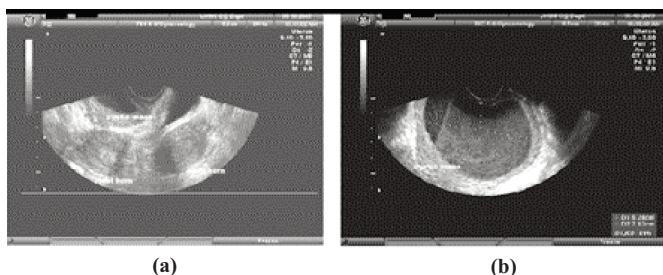
menstruation. A high index of suspicion is necessary to diagnose these disorders and an adequate workup is essential. This report will present a case of *uterus bicornis bicollis*, unilateral imperforate vagina and ipsilateral renal agenesis. The incidence, classification, workup and management will be reviewed.

CASE REPORT

A 17-year old nulliparous female presented with abnormal vaginal bleeding and painful periods. Menarche was at age 12 years with normal pubertal events. Her menses were normal until about a year before presentation when she developed heavy menses and approximately 10 days of post-menstrual spotting. She also developed worsening dysmenorrhoea and an abnormal vaginal discharge. She became sexually active at age 14 years but did not give a history of dyspareunia, postcoital bleeding or any sexually transmitted infections. Her past medical/surgical history was not significant.

Physical examination was unremarkable except for the pelvic examination which revealed normal external genitalia, normal introitus and vagina except that the right lateral wall was bulging into the vaginal cavity and the cervix was deviated to the left. Bimanual pelvic examination revealed a large right cystic adnexal mass.

Pelvic ultrasound scan revealed what was reported as a "bicornuate uterus and a large 8 x 8 cm diameter mass beneath the bladder and to the right of the cervix" (Fig. 1: a, b). The left ovary was normal but the right ovary was not



Pelvic ultrasound findings showing in Fig. 1a two separate uterine cornua and an inferiorly located cystic mass. Fig. 1b shows more clearly the hyper-echoic material in the vagina.

identified. Based on the above findings a diagnosis of a bicornuate uterus with a large right endometrioma was made.

After appropriate counselling and consent, the patient had a diagnostic laparoscopy which revealed two uterine horns, normal Fallopian tubes and ovaries; no endometriotic deposits nor sign of a pelvic mass was noted (Fig. 2). Intravenous urogram and abdominal ultrasound scan revealed a solitary normal left kidney. A repeat transvaginal ultrasound scan confirmed *uterus didelphys* with an imperforate hemivagina. A final diagnosis of *uterus bicornis bicollis*, imperforate hemivagina and ipsilateral renal agenesis was made. The patient consented to excision of the vaginal septum.

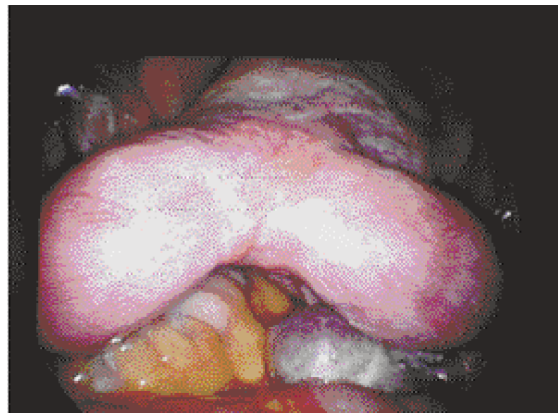


Fig. 2: Double uterus at diagnostic laparoscopy.

SURGICAL PROCEDURE

At the time of admission for surgery, copious quantities of foul smelling, cream-coloured discharge per introitus was noted; a high vaginal swab was taken and she was started on co-amoxicillin-clauvalinic acid twice daily.

Examination under anaesthesia revealed a complete longitudinal vaginal septum with a right haematocolpos. The septum was excised; a pyocolpos, an erythematous and inflamed vaginal mucosa and a second cervix were noted. The obstructed cervix appeared hyperaemic and flush with the vaginal fornices. After resection of the vaginal septum, an acroflavin pack was left in the vagina overnight. Swabs taken at admission and during the operation grew group B *Streptococcus* sensitive to co-amoxicillin-clauvalinic acid.

Her postoperative course was uneventful and when reviewed three months later, speculum examination revealed healed vaginal mucosa and two normal-looking cervixes and there were no further complaints of dysmenorrhoea.

DISCUSSION

Uterus bicornis bicollis with unilateral imperforate vagina and ipsilateral renal agenesis is an uncommon congenital anomaly in which the uterus and vagina are duplicated. The earliest case of "Double" uterus with unilateral haematocolpos was reported in 1925 (11).

Embryologically, the female genital tract develops almost entirely from the Müllerian ducts that appear in the first 6 weeks of intrauterine life. The Müllerian ducts begin as paired symmetrical structures that then fuse in the midline to form the uterus, cervix and upper part of the vagina. If each Müllerian duct develops separately without fusion at any point, the result will be two distinct hemiuteri, each with its own Fallopian tube, ovary, cervix and vagina. The exact cause of the vaginal septum is unknown, but may be caused by an embryonic arrest at 8 weeks gestation that simultaneously affects the Müllerian and metanephric ducts.

There is a tissue-specific factor called the hepatocyte nuclear factor 1 Beta (HNF1B) that plays an essential role in early development. Heterozygous mutations (SI51P, Q243,

and R137-K161) with the HNF1B gene are associated with juvenile diabetes, a variety of renal and genital tract malfunctions (13, 14). This type of gene mutation may be responsible for the anomalies seen in our patient and if that is so she may be at risk for early onset diabetes.

Renal agenesis commonly accompanies Müllerian duct malformations (Fig. 3), because they both generate from the

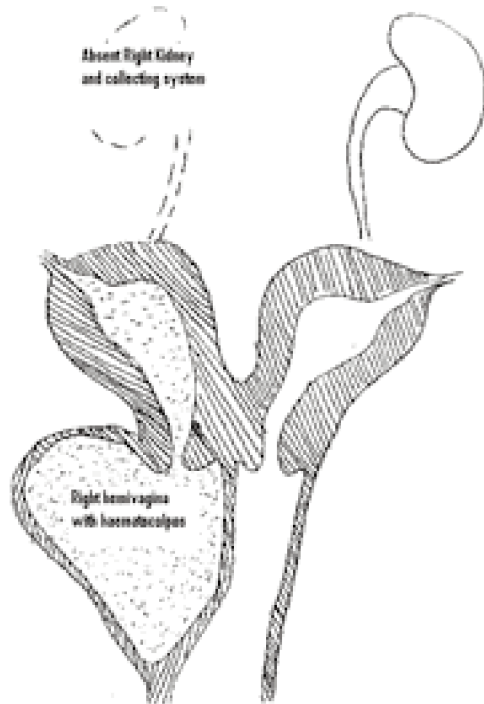


Fig. 3: Schematic view of pathology.

same ureteric bud (7). Vercellini *et al* (12) reported on the presence of a *uterus didelphys*, obstructed hemivagina and renal agenesis on the right side as in this case.

In 1989, the American Society for Reproductive Medicine developed a classification system that allows organization according to major uterine anatomical types. Table 1 classifies Müllerian anomalies, whereas Table 2 lists the classification of vaginal anomalies. The case presented herein has a Class III uterine anomaly and a Class IIa vaginal anomaly.

The presentation of obstructive longitudinal vaginal septum is variable and ranges from no symptoms to cyclic pelvic pain and abnormal bleeding. They may also present on rare occasions with fever, peritonitis, purulent vaginal discharge and leukocytosis, leading to a presumptive diagnosis of pelvic inflammatory disease.

It is common for these patients to develop haematometra, haematosalpinx and endometriosis. In *uterus didelphys* with unilateral imperforate vagina, the most common symptoms are cyclic dysmenorrhoea and abdominopelvic pain. If the vagina or uteri communicate at any point, abundant and often foul-smelling leucorrhoea results (15).

Table 1. ASRM classification of Müllerian anomalies

| Classification | Anomaly |
|-------------------------------|---|
| Class I (agenesis/hypoplasia) | a. Vaginal b. Cervical c. Fundal d. Tubal e. Combined anomalies |
| Class II (unicornuate) | a. Communicating b. Noncommunicating c. No cavity d. No horn |
| Class III (didelphys) | Didelphys |
| Class IV (bicornuate) | a. Complete b. Partial |
| Class V (septate) | a. Complete b. Partial |
| Class VI (Arcuate) | Arcuate |
| Class VII (DES related) | DES related |

ASRM, American Society of Reproductive Medicine; DES, diethylstilbestrol.

Table 2. Vaginal classification

| Classification | Anomaly |
|----------------|---|
| Class I | Transverse a. Obstructing b. Nonobstructing |
| Class II | Longitudinal a. Obstructing b. Nonobstructing |
| Class III | Stenosis/iatrogenic |

Magnetic resonance imaging (MRI) may be an important adjunct for diagnosis because of its ability to clarify the anatomy of the uterus and vagina (16, 17). Magnetic resonance imaging has been found to be 100% sensitive and 83–100% specific in the diagnosis of this anomaly (15, 16) and is considered to be more sensitive for imaging soft tissue pelvic anatomy than CT. However, both of these modalities are expensive. Ultrasound can confirm the absence of one kidney in these patients however, which in the presence of an obstructed genital tract will lead to the correct diagnosis 100% of the time (16).

Resection of the vaginal septum was effected easily as this patient was sexually active. In a series described by Altintas (8) transvaginal resection of the vaginal septum was done in six of seven cases; for the other patient, the blind vagina with haematocolpos and attending uterus were extirpated by an abdominal approach. Kim *et al* (9) described the use of an operative hysteroscope to excise the septum through the small aperture of the hymen in a patient who was virginal so as to preserve the anatomy of the hymen.

Obstetric concerns included an increased risk of miscarriage, prematurity, intrauterine growth restriction (IUGR), abnormal foetal position and increased Caesarean section rate. Due to the absence of intrauterine septae, pregnancies in didelphic uteri are not as prone to miscarriage or prematurity as other uterine anomalies. Ludmir *et al* (18) in 1990 reviewed the obstetric outcomes in 10 patients with didelphic uteri; 80% of the fetuses survived. This study also incorporated reproductive outcomes in unicornuate, bicornuate and septate uteri. A term pregnancy was achieved in 60% of the didelphic group, the highest rate of all the different types of uterine anomalies studied.

The prompt and accurate diagnosis of disorders of development of the female reproductive tract is essential to prevent complications from acute illness and preserve future fertility. Many cases are improperly diagnosed; we therefore emphasize the need for paediatricians, radiologists, gynaecologists and paediatric surgeons to become familiar with these disorders to avoid complications and diagnostic delay.

REFERENCES

1. Attaran M, Falcone T, Gidwani G. Obstructive Müllerian anomalies. In: Gidwani G, Falcone T, eds. *Congenital Malformations of the Female Genital Tract. Diagnosis and management*. Philadelphia: Lippincott Williams & Wilkins; 1999: 145–68.
2. Candiani GB, Fedele L, Candiani M. Double uterus, blind hemivagina and ipsilateral renal agenesis: 36 cases and long-term follow-up. *Obstet Gynecol* 1997; **90**: 26–32.
3. Heinonen PK. Clinical implications of the didelphic uterus: long-term follow-up of 49 cases. *Eur J Obstet Gynecol Reprod Biol* 2000; **91**: 183–90.
4. Banerjee R, Laufer DP. Reproductive disorders associated with pelvic pain. *Semin Pediatr Surg* 1998; **7**: 52–61.
5. Rock JA, Zacur HA, Dlugi AM, Jones HW Jr, TeLinde RW. Pregnancy success following surgical correction of imperforate hymen and complete transverse vaginal septum. *Obstet Gynecol* 1982; **59**: 448–51.
6. Stassart JP, Nagel TC, Prem KA, Phipps WR. Uterus didelphys, obstructed hemivagina, and ipsilateral renal agenesis: the University of Minnesota experience. *Fertil Steril* 1992; **57**: 756–61.
7. Crosby WM, Hill EC. Embryology of the Müllerian duct system. Review of present-day theory. *Obstet Gynecol* 1962; **20**: 507–15.
8. Altıntaş A. Uterus didelphys with unilateral imperforate hemivagina and ipsilateral renal agenesis. *J Pediatr Adolesc Gynecol* 1998 Feb; **11**: 25–7.
9. Kim TE, Lee GH, Choi YM, Jee BC, Ku SY, Suh CS et al. Hysteroscopic resection of the vaginal septum in uterus didelphys with obstructed hemivagina: a case report. *J Korean Med Sci* 2007; **22**: 766–9.
10. Rock JA, Jones Jr. HW. The double uterus associated with an obstructed hemivagina and ipsilateral renal agenesis. *Am J Obstet Gynecol* 1980; **138**: 339–42.
11. Wilson JS. A case of double uterus and vagina with unilateral hematocolpus and hematometra. *J Obstet Gynaecol Br Emp* 1925: **32**: 127–8.
12. Vercellini P, Daguati R, Somigliana E, Viganò P, Lanzani A, Fedele L. Asymmetric lateral distribution of obstructed hemivagina and renal agenesis in women with uterus didelphys: institutional case series and a systematic literature review. *Fertil Steril* 2007; **87**: 719–24.
13. Yorifuji T, Kurokawa K, Mamada M, Imai T, Kawai M, Nishi Y et al. Neonatal diabetes mellitus and polycystic, dysplastic kidneys: Phenotypically discordant recurrence of a mutation in the hepatocyte nuclear factor-1beta gene due to germline mosaicism. *J Clin Endocrinol Metab* 2004; **89**: 2905–8.
14. Bingham C, Bulman MP, Ellard S, Allen LI, Lipkin GW, Hoff WG et al. Mutations in the hepatocyte nuclear factor-1beta gene are associated with familial hypoplastic glomerulocystic kidney disease. *Am J Hum Genet* 2001; **68**: 219–24.
15. Rock JA. Congenital outflow tract obstruction. In: Adashi EY, Rock JA, Rosenwaksz, eds. *Reproductive Endocrinology, Surgery and Technology*. Philadelphia: Lippincott-Raven; 1996: 1445–74.
16. Fedele L, Dorta M, Brioschi D, Massari C, Candiani GB. Magnetic resonance evaluation of double uteri. *Obstet Gynecol* 1989; **74**: 844–7.
17. Pellerito JS, McCarthy SM, Doyle MB, Glickman MG, DeCherney AH. Diagnosis of uterine anomalies: relative accuracy of MR imaging, Endovaginal sonography, and hysterosalpingography. *Radiology* 1992; **183**: 795–800.
18. Ludmir J, Samuels P, Brooks S, Mennuti MT. Pregnancy outcome of patients with uncorrected uterine anomalies managed in a high-risk obstetric setting. *Obstet Gynecol* 1990; **75**: 906–10.